

# Novel Visualization of the Topographical Model of MS Using 3D Rendering of Quantified MRI



S. Krieger<sup>1</sup>, P. Izbicki<sup>2</sup>, K. Leyden<sup>2</sup>, L. Bajus<sup>2</sup>, F. Faust<sup>2</sup>, M. Schrier<sup>2</sup>, V. Keshavan<sup>2</sup>, T. Hoyt<sup>3</sup>, J. Foley<sup>3</sup>

1. Icahn School of Medicine at Mount Sinai, New York City, NY; 2. Octave Bioscience Inc., Menlo Park, CA; 3. Rocky Mountain MS Clinic, Salt Lake City, UT

ECTRIMS 2024

## Introduction

Brain MRIs contain hundreds of images across an array of sequences, and standard radiology reports may not comprehensively convey the total burden of disease.

The topographical model of MS (Krieger et al., 2016) was developed as a visualization of MS that depicts localized lesions in a pool of variable reserve. To date, this model has only been used to show emblematic disease phenotypes rather than utilizing MRI data to depict individual patients. We present the first visualizations of patients in the topographical model using novel 3D brain MRI technology.

## Objectives

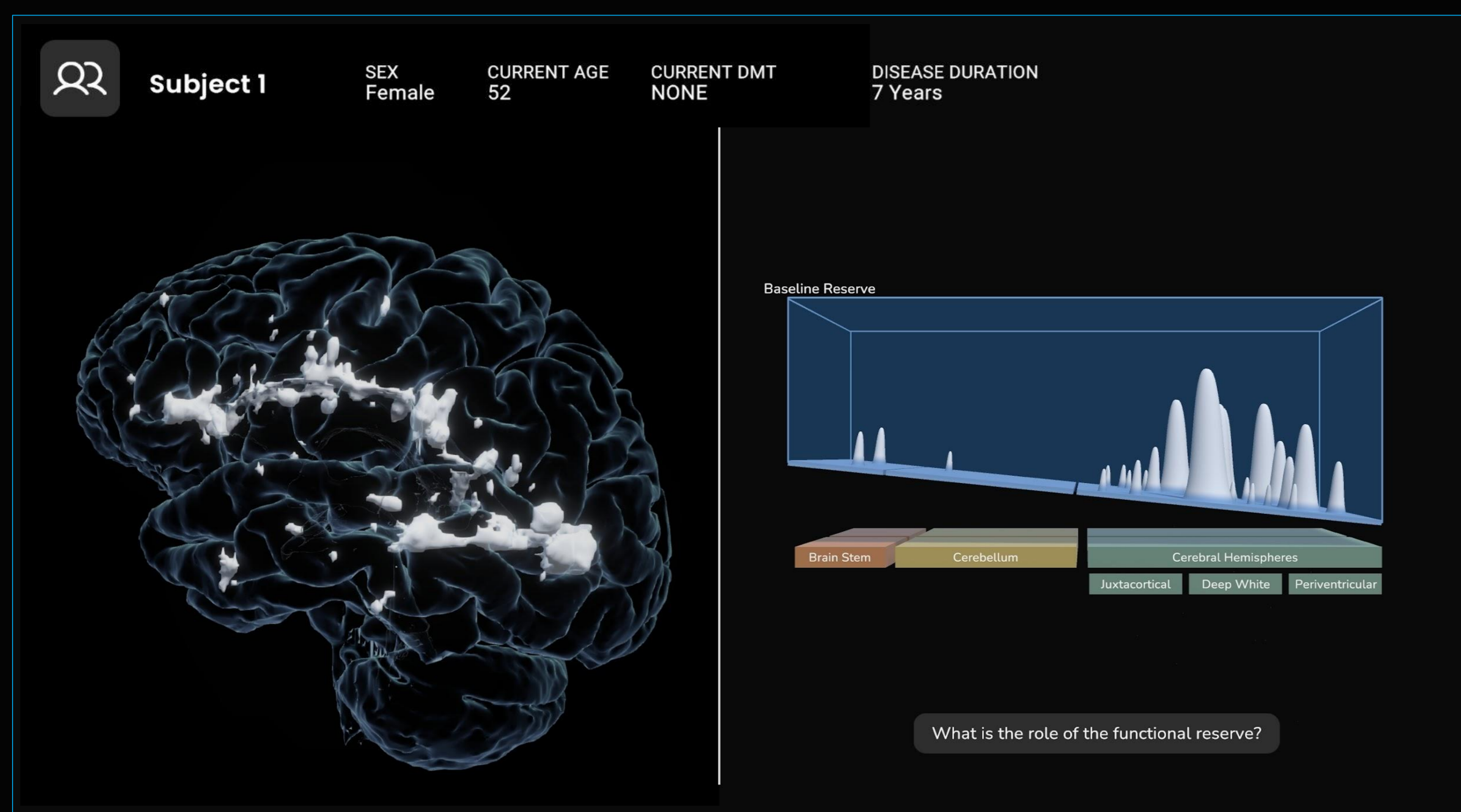
Demonstrate how three dimensional (3D) brain MRI can be visualized utilizing the topographical model of multiple sclerosis to facilitate assessment of disease burden in individual patients with MS (PwMS).

## Results & Visualization

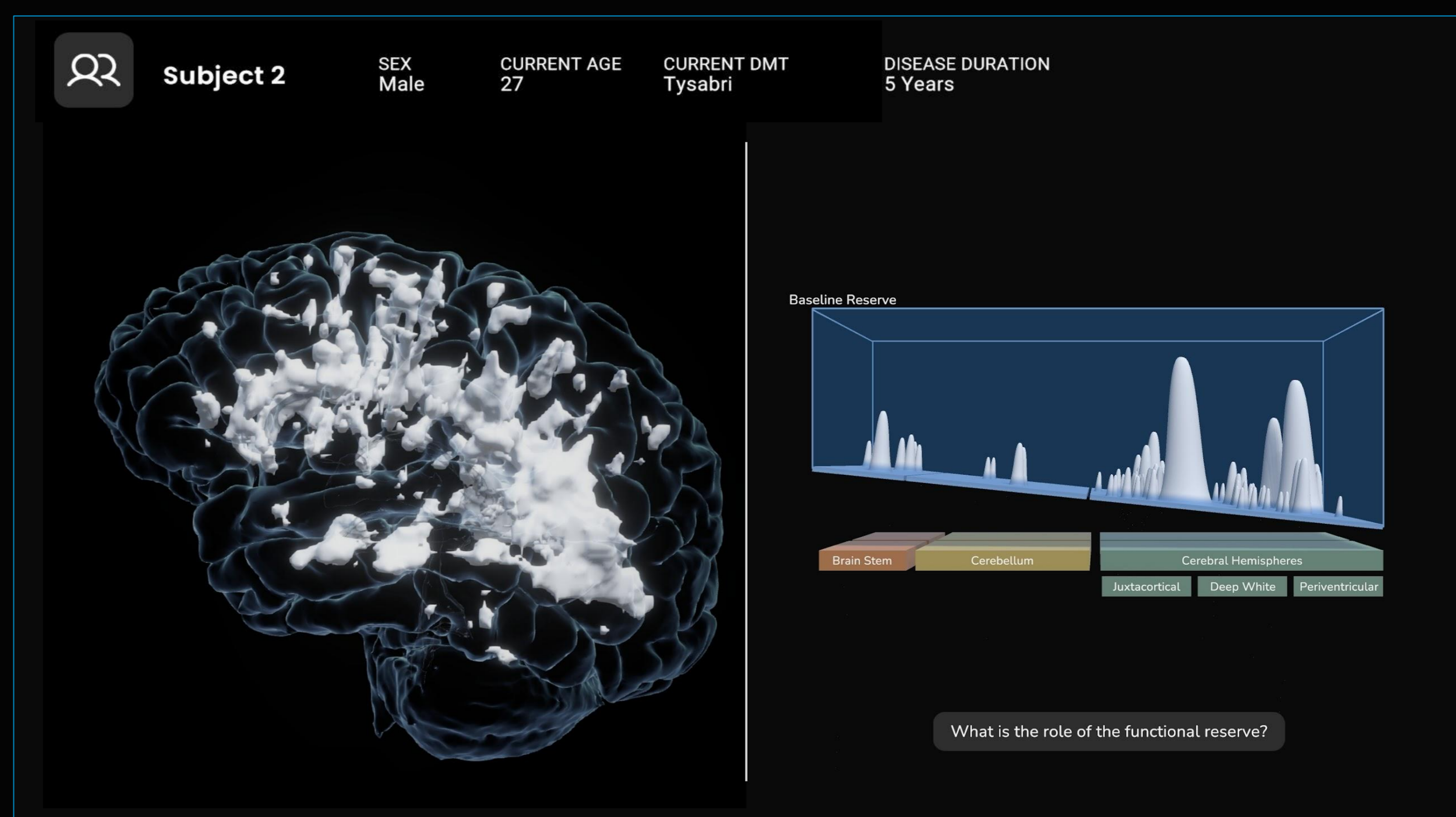
Novel visualizations of PwMS in the topographical model are shown, demonstrating the feasibility of this technique to depict radiographic burden of disease. Each 3D brain MRI is paired with a topographical model rendering showing lesion size/severity, surface morphology, and laterality/localization in juxtacortical, subcortical, periventricular, and segmented infratentorial regions. Clinical factors including age, sex, race, current treatment and disease duration are shown for each PwMS.

- Moderate Lesion Burden Case
  - 53 year-old Female with RRMS for 7 years, PDDS = 4, No DMT
- High Lesion Burden Case
  - 27 year-old Male with RRMS for 6 years, PDDS = 2, DMT= Tysabri

The clinical MRI report for both cases read as follows: "Innumerable areas of subcortical, pericallosal and periventricular T2 hyperintensity typical of MS. Several posterior fossa lesions are again identified. Several lesions demonstrate volume loss typical of long-standing MS."



**Figure 1:** The application displaying side by side view of an individual PwMS brain anatomy with moderate lesion burden in their native 3D brain space (left) which is then translated into the topographical model (right).



**Figure 2:** The application displaying side by side view of an individual PwMS brain anatomy with high lesion burden in their native 3D brain space (left) which is then translated into the topographical model (right).

Scan QR Code for 3D Visualization Video 



## Methods

Using a well-characterized cohort of patients with relapsing-remitting multiple sclerosis, case-depiction feasibility was assessed utilizing MRIs with 3D T1 & T2 FLAIR sequences, processed through NeuroQuantMS 3.1 (Cortechs.ai) and THINQ (CorticoMetrics) to extract lesion counts and volumes, parenchymal volumetrics, and 3D surface meshes. Volumetric and lesion meshes were then grouped into FBX files and imported into Unity for rendering.

Lesion localizations were mapped and scaled for depiction according to topographical model parameters. A framework for consolidating 3D information was constructed to maintain as much lesion detail as possible in the 2D topographical model plane. Methodological considerations included:

### 1) Defining the width and height of each topographical peak

- There will be a minimum and a maximum topographical peak size which will have a corresponding lesion volume defined by MRI lesion voxel segmentation.
- Lesion volumes will be linearly interpolated along these thresholds clinically-relevant thresholds to generate a relative topographical peak height and width.

### 2) Determining lesional placement of the topographical map

- The regional sub-category is defined by McDonald criteria anatomical region and laterality
- The distance from the center of the brain (0,0,0) to the center of the lesion (x,y,z) will be used to determine the placement of the lesion along the depth axis (with the brainstem comprising the shallow end of the reserve pool, and the hemisphere sub-compartments at the deep end of the pool).

## Conclusions

### Practice Gap:

- Prior work presented by Octave (Leyden et al. 2024) has revealed variability in interpretation of standard of care MS MRI reports, revealing gaps in recognition of lesion burden and localization.
- Work by Solomon et al. (2021) has shown that neurologists, even when viewing MRIs directly, fail to accurately report lesion location and implications for MS diagnosis.
- The topographical model of MS visual depiction of MRIs can help with both of these gaps, by intuitively showing MS lesion burden and localization and thus filling the gaps left by MRI reports and traditional interpretation.

### Implications:

- There remains suboptimal interpretation of MRI findings in clinical practice, both in terms of MRI reports of limited utility and under-appreciation of the importance of lesion localization. Octave's 3D brain imaging technology can be used to depict patients in the topographical model of MS, which has never before been used to visualize MRI lesions and individual MS patients.
- This project can be further developed as a novel way of depicting subclinical MS disease burden with prognostic implications.
- Additional work will integrate parenchymal measures of reserve as well as inclusion of spinal cord lesions.